


**IDBR
INFECTIOUS
DISEASE
BOARD REVIEW**
AUGUST 16-20, 2025



Daily Question Preview: Day 4

Moderator: Roy Gulick, MD, MPH


8/5/2025

1

PREVIEW QUESTION

4.1 For which of the following infections would life long suppressive therapy be indicated for a patient with an initial CD4 count <50 cells and high viral load, regardless of subsequent success of ART regimen in terms of CD4 count and viral load?

- A. Disseminated histoplasmosis
- B. Cryptococcal meningitis
- C. Coccidioides meningitis
- D. Miliary tuberculosis
- E. Disseminated Mycobacterium avium complex



1 of 2


2

PREVIEW QUESTION

4.2 A 43-year-old man with HIV has CD4 900-1200 and HIV RNA consistently <200 copies over the last 11 years.

Do you recommend starting ART?

- A. Yes, all current guidelines recommend starting
- B. No, he's a long-term non-progressor and doesn't need ART
- C. No, he should wait until his viral load level is confirmed >200 copies/ml
- D. No, he should wait until CD4 is confirmed <500 cells/uL




1 of 2

3

PREVIEW QUESTION

4.3 25-year-old man presents with newly diagnosed HIV
Had an episode c/w acute seroconversion syndrome 4 months ago
Initial HIV RNA 40,000; CD4 443 cells/uL
He wants to start ARV therapy
A baseline genotype is ordered that shows an M184V mutation.
Which of the following drugs will have reduced susceptibility with this mutation?

- A. Efavirenz
- B. Zidovudine
- C. Tenofovir
- D. Etravirene
- E. Emtricitabine



1 of 2

4

PREVIEW QUESTION



4.4 A 22-year-old man presents with fever, mouth pain, and skin rash. PE reveals 3 small oral ulcers and diffuse macular rash. Labs show WBC 3K, platelets 89K, monospot negative, RPR NR, HIV antibody negative, HIV RNA 1,876,000 cps/ml.

Which statement is correct?

- A. ART should not be offered
- B. ART would decrease his symptoms
- C. ART would not decrease ongoing transmission
- D. ART has long-term clinical benefits in this setting

1 of 2

5

PREVIEW QUESTION



4.5 50-year-old woman with HIV (CD4 20, HIV RNA 500,000) presents with fever and headache. Not on antiretroviral therapy (ART). Diagnosed with cryptococcal meningitis

Started on induction therapy (liposomal amphotericin plus 5FC)

When should she be started on ART?

- A. Start ART at the same time as anti-fungal therapy
- B. About 4 weeks after starting anti-fungal therapy
- C. 6 months after starting anti-fungal therapy
- D. After completing a full course of maintenance anti-fungal therapy

1 of 2

6

PREVIEW QUESTION



4.6 45-yo man with HIV (CD4 11, HIV RNA 300,000) presents with fever, diarrhea and weight loss. Started on dolutegravir + tenofovir/emtricitabine. Two weeks later, develops enlarged supraclavicular lymph node. Biopsy: necrotizing granulomas and AFB; cultures grow MAC

What would you recommend?

- A. Stop ART and initiate treatment for MAC
- B. Continue ART; initiate treatment for MAC
- C. Start steroids and stop all other treatments

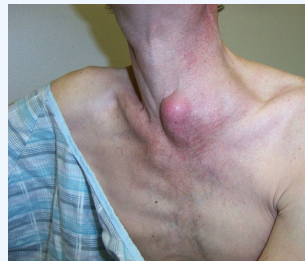

Image from Riddell J, J Translational Med, 2007

1 of 2

7

PREVIEW QUESTION



4.7 A 19-year-old Iraqi immigrant is hospitalized for 2-day history of fever and abdominal pain.

He has had similar episodes on at least 3 previous occasions over the past 7 years. At the first episode he underwent appendectomy; the appendix path was normal. Subsequent episodes resolved spontaneously after 2-3 days.

Exam:

T 102.2; pulse 114; no rash

Abdominal guarding, rebound tenderness, hypoactive bowel sounds

Labs:

WBC 16,650; UA normal

BMP & LFTs normal

No occult blood in stool

CT of abdomen and pelvis normal

1 of 3

8

**4.7 What is the most likely diagnosis?**

- A. Hereditary angioneurotic edema
- B. Familial Mediterranean fever
- C. Systemic lupus erythematosus
- D. Crohn's disease
- E. Acute intermittent porphyria

2 of 3

9



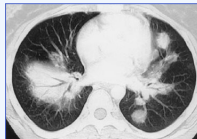
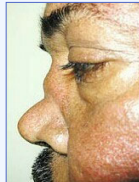- 4.8** A 38-year-old man is seen for a 6-week history of cough, intermittent fever and night sweats.
- He has had nasal stuffiness for 4-5 months with occasional epistaxis. He lives in Philadelphia, and 6 months ago traveled to Cincinnati on business.
- He has no pets and takes only an OTC decongestant. He denies use of illicit substances, including intranasal cocaine.

1 of 4

10



- 4.8** Exam:
- T 100.2; RR 18;
- Nasal deformity with perforation of septum
- Lungs clear; rest of exam normal
- Labs:
- WBC 6,900 with normal differential
- UA 30-50 RBC; BMP normal
- Chest CT: bilateral nodules with cavitation



2 of 4

11



- 4.8** Which of the following will most likely support the diagnosis?
- A. c-ANCA
 - B. Anti-glomerular basement membrane Ab
 - C. Urine toxicology screen
 - D. Angiotensin converting enzyme (ACE)
 - E. Pulmonary angiogram

3 of 4

12

PREVIEW QUESTION



4.9 55-year-old man presents with R hip pain
H/O COPD requiring steroids frequently
HIV diagnosed 17 years ago
On TDF / FTC / EFV for 10 years; originally on IND / AZT / 3TC
Initial HIV RNA 340,000; CD4 43 cells/ul
Now HIV RNA < 50 c/ml; CD4 385 cells/ul
Electrolytes NL; Creat 1.3; Phos 3.5 Ca 8.5
Mg 2.1, alk phos 130; U/A neg
R Hip film unremarkable

1 of 3

13

PREVIEW QUESTION



4.9 Which if the following is the most likely underlying cause of his hip pain?

- A. Osteonecrosis of femoral head
- B. Fanconi's syndrome
- C. Vitamin D deficiency
- D. Tenofovir bone disease
- E. Hypogonadism

2 of 3

14

PREVIEW QUESTION



4.10 35-year-old man presents with complaints of increasing fatigue, headache, SOB / DOE
HIV diagnosed 4 months ago with PCP; intolerant to TMP/SMX
Now on TAF / FTC / BIC + PCP Prophylaxis with Dapsone
Claims adherence to all meds; "Doesn't miss a dose!"
Normal PE
Pulse Ox 85%; CXR no abnormalities
ABG: 7.40 / 38 / 94 / 96% (room air)

1 of 3

15

PREVIEW QUESTION



4.10 Which of the following is the most likely underlying cause of his symptoms?

- A. Recurrent PCP
- B. IRIS reaction
- C. Drug toxicity
- D. Pulmonary embolus
- E. Patent foramen ovale

2 of 3

16

PREVIEW QUESTION



- 4.11** 38-year-old woman presents with a 2-day history of fever, headache and stiff neck; similar episodes have occurred every 3-4 months over several years, with spontaneous abatement after 4-5 days
- She is sexually active only with her husband of 8 years, and has 2 children at home (ages 2 and 5 years)
- On exam, T 99.8°F and other vital signs are normal; she has evidence of meningismus, but is alert and oriented and with no focal findings
- Laboratory studies are normal
- CSF analysis reveals a WBC of 70/mm³ (100% lymphs), glucose of 60 mg/dL, and protein of 100 mg/dL; Gram stain negative

1 of 3

17

PREVIEW QUESTION



- 4.11** Which of the following is the most likely etiology of this patient's meningitis?
- A. Coxsackie A virus
 - B. Coxsackie B virus
 - C. Parvovirus B19
 - D. Herpes simplex virus type 2
 - E. Human herpesvirus 6

2 of 3

18

PREVIEW QUESTION



- 4.12** A 30-year-old heart transplant has received acyclovir for the past 60 days for cutaneous HSV infection. The lesions are now progressive despite high-dose intravenous therapy.
- Instead of healing, as shown a previous slide, the lesions progress despite antiviral therapy.
- A deficiency or alteration of which of the following is the most likely cause for disease progression?
- A. Ribonucleotide reductase
 - B. Reverse transcriptase
 - C. Protease
 - D. Thymidine kinase
 - E. DNA polymerase

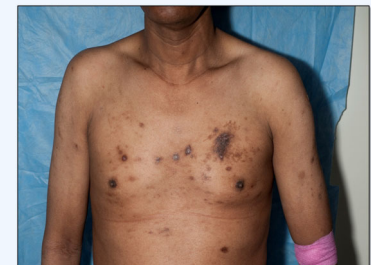1 of 2

19

PREVIEW QUESTION



- 4.13** A patient who was recently found to be HIV positive...
- (CD4=10 cells/uL, VL=2 mil copies)
- Has noted the lesions shown on the following PowerPoint developing on his trunk, face and extremities over the past 8 months.
- Otherwise, he felt fine.



1 of 3

20



4.13 What would you expect to be causative agent for these lesions?

- A. HHV-6
- B. HHV-8
- C. EBV
- D. JC Virus
- E. BK Virus

2 of 3

21



4.14 A 26-year-old woman with HIV on TAF/emtricitabine + efavirenz with CD4 630 and VL suppressed below detection becomes pregnant. What do you recommend regarding ART?

- A. Discontinue ART until 2nd trimester
- B. Change TAF to zidovudine
- C. Change efavirenz to bictegravir
- D. Continue current regimen

1 of 2

22



4.15 A 32-year-old woman is seen for a bad sore throat for 4 days

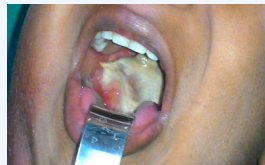Recently returned from her sister's wedding in Kazakhstan
She c/o odynophagia and a low-grade fever

T 100.2F; P 126; BP 118/74.

HEENT: Submandibular swelling with gray exudate coating posterior pharynx.

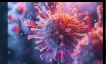An S3 gallop is heard.

EKG shows 1st degree AV nodal block, QT prolongation, and ST-T wave changes.



1 of 3

23



4.15 What is the most likely diagnosis?

- A. Streptococcal pharyngitis
- B. Kawasaki disease
- C. Vincent angina
- D. Diphtheria
- E. Candida

2 of 3

24