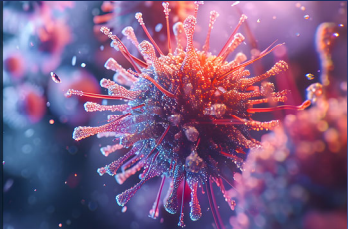


IDBR
**INFECTIOUS
DISEASE
BOARD REVIEW**
AUGUST 16-20, 2025



Daily Question Preview: Day 2

Moderator: Andrew Pavia, MD


8/5/2025

1

PREVIEW QUESTION

2.1 Which quinolone has activity against MRSA?

- A. Ciprofloxacin
- B. Moxifloxacin
- C. Trovafloxacin
- D. Delafloxacin
- E. Levofloxacin




1 of 2

2

PREVIEW QUESTION

2.2 What is the major advantage of tedizolid compared to linezolid?

- A. Longer half life
- B. Better penetration of prostate
- C. Better CSF Penetration
- D. Wide spectrum of activity against anaerobes
- E. More effective in clinical studies for VRE




1 of 2

3

PREVIEW QUESTION

2.3 A 54-year-old woman presents with fever, chills, and oliguria one week after travel to Malaysia.
Vitals: 39.0°C, HR 96/min, RR 24/min, BP 86/50
Labs: Hct 31%, platelets 14,000/μl, Cr of 3.2 mg/dL.
Peripheral blood smear has intraerythrocytic forms that are morphologically consistent with Plasmodium malariae.
What is the most likely infectious agent causing the patient's illness?

- A. Plasmodium malariae
- B. Plasmodium knowlesi
- C. Plasmodium vivax
- D. Plasmodium falciparum
- E. Babesia microti



1 of 2

4

PREVIEW QUESTION



2.4 A 33-year-old woman is traveling to Uganda to do field studies in anthropology. She is two months pregnant.

Which of the following do you prescribe for malaria prophylaxis?

- A. Doxycycline
- B. Chloroquine
- C. Mefloquine
- D. Atovaquone/proguanil
- E. No prophylaxis

1 of 2

5

PREVIEW QUESTION



2.5 A 50-year-old female with alcohol substance use disorder suffered a provoked dog bite

Bite was cleansed, tetanus toxoid given, and the dog placed under observation

Patient is post-elective splenectomy for ITP; she received pneumococcal vaccine one year ago

One day later, the patient is admitted to the ICU in septic shock with severe DIC and peripheral symmetric gangrene of the tips of her fingers/toes

Which one of the following is the most likely etiologic bacteria?

- A. *Pasteurella canis*
- B. *Capnocytophaga canimorsus*
- C. *Fusobacterium* spp.
- D. *Bartonella henselae*

1 of 2

6

PREVIEW QUESTION



2.6 18-year-old with jaundice
Presents with 5d of headache, fever, diarrhea, vomiting, chest pain
PMH – Open fractures of all metatarsals with pins x 3 mo
SH – home tattoos; lives with parents and pregnant girlfriend; dogs and rats; swam in freshwater dam 1 week before symptom onset; cuts grass; multiple tick bites; Maryland
T 39.4; BP 118/62 (then on pressors); P 91; 97% RA
Icteric, non-injected, no murmurs
Diffuse petechial rash; purple macules on ankle
WBC 11,740 (92.4 P, 0.8B, 2% L); Hb 14.2; Plt 47,000
Creatinine 0.9-3.4; CRP 10.1; Tbili 4.1 (direct 3.7); ALT/AST 26/53; CK 887
HIV Ab neg; SARS-CoV-2 PCR neg; Monospot - neg

1 of 3

7

PREVIEW QUESTION



2.6 What is the cause of his illness?

- A. Acute hepatitis A
- B. *Babesia microti*
- C. Tularemia
- D. *Leptospira icterohaemorrhagiae*
- E. HSV

2 of 3

8

PREVIEW QUESTION



2.7 Acute Hepatitis in Uganda

42-year-old female has malaise and RUQ pain; she just returned from 2 months working at an IDP camp in north Uganda. She endorses tick and other 'bug' bites and swam in the Nile. 1st HAV vaccine 2 days before departure. Prior HBV vaccine series.

Exam shows no fever, vitals are normal. RUQ tender. Mild icteric. ALT 1245 IU/ml; Hb 13.4 g/dl; TB 3.2 mg/dl; WBC 3.2k nl differential.

Which test result is most likely positive?

- A. Ebola PCR
- B. IgM anti-HEV
- C. IgM anti-HAV
- D. Schistosomiasis "liver" antigen
- E. 16S RNA for Rickettsial organism

1 of 2

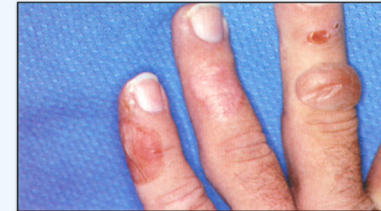9

PREVIEW QUESTION



2.8 Hepatitis C and a Rash

A 44-year-old, anti-HCV and HCV RNA positive man feels bad after a recent alcohol binge. He has a chronic rash on arms that is worse and elevated ALT and AST.



O'Connor Mayo Clin Proc 1998

1 of 3

10

PREVIEW QUESTION



2.8 HCV with a Rash

What is the most likely dx?

- A. Cirrhosis due to HCV and alcohol
- B. Necrolytic acral erythema
- C. Porphyria cutanea tarda
- D. Essential mixed cryoglobulinemia
- E. Yersinia infection

2 of 3

11

PREVIEW QUESTION



2.9 A young woman undergoes upper endoscopy for unexplained nausea & vomiting. The stomach appears normal. Surveillance biopsies are taken & the gastric biopsy urease test is positive.

What are the biopsies are most likely to show?

- A. Hp organisms, but no gastric or esophageal inflammation
- B. Hp organisms plus gastric inflammation (gastritis)
- C. Hp organisms plus esophagitis
- D. Neither Hp organisms, nor inflammation because the urease test is often false positive with a normal endoscopy

1 of 2

12

PREVIEW QUESTION



2.10 A 25-year-old Peace Corps worker in Madagascar reports passing thin, white, flat tissue fragments in her stool. The microbiology lab reports the tissue fragments are proglottid segments of *Taenia solium*.

What is a long-term complication that can occur as a result of infection with the larval form of this parasite?

- A. HTLV-1 infection
- B. Bladder cancer
- C. Appendicitis
- D. Liver abscess
- E. Seizures

1 of 2

13

PREVIEW QUESTION



2.11 A 35-year-old female presents for a post-travel evaluation six weeks after return from a trip to Costa Rica. During travel, she had fever and diarrhea and self-administered azithromycin 500mg PO x 3 days. Since returning, she has had intermittent abdominal pain, bloating, and loose stools. A multiplex PCR panel including common bacteria, viruses, and intestinal protozoa is negative.

Which of the following would be the most appropriate next step in management for this patient?

- A. Serologic testing for Celiac disease
- B. Referral for endoscopy
- C. Initiate treatment with nitazoxanide
- D. Reassurance and expectant management
- E. Modified acid-fast stain of a stool sample

1 of 2

14

PREVIEW QUESTION



2.12 A 43-year-old female presents with several days of watery diarrhea and one day of gross blood in her stools. Two other members of her family have similar symptoms. None of the family members have had a fever and she is afebrile on exam. Laboratory studies are notable for a hematocrit of 28%, platelets of 80,000 per ml and creatinine 2.4 mg/dl.

In addition to stool-based diagnostics, which of the following would be the most appropriate next step in management for this patient?

- A. Start IV Ceftriaxone
- B. Withhold antibiotic therapy
- C. Start PO Azithromycin
- D. Start IV Meropenem
- E. Start PO Vancomycin

1 of 2

15

PREVIEW QUESTION



2.13 47-year-old woman
Recurrent episodes of bronchitis, recently more exacerbations; tired
One episode of documented bacterial pneumonia and sinusitis
Immunoglobulin levels:
– IgG 500 (normal 523-1482)
– IgA <10 (normal 51-375)
– IgM 165 (normal 37-200)

1 of 3

16

**2.13 What is the next step?**

- A. IgG subclasses and titers against tetanus and pneumococcus. If low, consider IVIG.
- B. Repeat IgG levels. If low, consider IVIG.
- C. Skin tests for DTH. If anergic, consider IVIG.
- D. Titers against tetanus and pneumococcus, immunize, and repeat. If low, consider IVIG.
- E. Check MBL levels. If low, consider IVIG.

2 of 3

17



- 2.14** A 35-year-old male suffers a clenched fist injury in a barroom brawl. He presents 18 hours later with fever and a tender, red, warm fist wound. Gram stain of bloody exudate shows a small gram-negative rod with some coccobacillary forms. The aerobic culture is positive for viridans streptococci

Which one of the following organisms is the likely etiologic agent?

- A. *Viridans streptococci*
- B. *Eikenella corrodens*
- C. *Peptostreptococcus*
- D. *Fusobacterium species*

1 of 2

18



- 2.15** The morning after families had arrived at a camp for a week-long retreat, approximately one-third of participants had developed nausea (65%), vomiting (44%), abdominal cramps (85%) and diarrhea (94%) during the night. The night prior, they shared a meal which consisted of a casserole containing macaroni, frozen mixed vegetables, ground beef, turkey, and gravy. The mean onset of symptoms was 11 hours after the meal. All affected persons were substantially improved within 24 hours after onset and there were no secondary cases.

Which one of the following is most likely responsible for this outbreak?

- A. *Staph aureus*
- B. *Clostridium perfringens*
- C. Enterotoxigenic *E. coli*
- D. *Listeria monocytogenes*
- E. Norovirus

1 of 2

19