

BR4 Board Review - Day 4
Moderator - Roy Gulick, MD

IDBR

INFECTIOUS DISEASE

BOARD REVIEW

AUGUST 16-20, 2025



Board Review: Day 4

Moderator: Roy Gulick, MD

Faculty: Drs. Bloch, Gandhi, Maldarelli, Masur, Saag, and Tunkel

7/18/2025


1

BOARD REVIEW DAY 4

INFECTIOUS DISEASE

BOARD REVIEW

2025



#46 A 22-year-old man asks about HIV pre-exposure prophylaxis (PrEP) options. His friend takes “on-demand” PrEP and he asks your opinion.

What do you respond?

- A. On-demand PrEP cannot be recommended because it is not FDA-approved
- B. On-demand is not recommended in current guidelines
- C. On-demand PrEP has only been studied with tenofovir disoproxil fumarate (TDF)/emtricitabine (FTC)
- D. On-demand PrEP has not been studied in men-who-have-sex-with-men (MSM)

1 of 2


2

BOARD REVIEW DAY 4

INFECTIOUS DISEASE

BOARD REVIEW

2025



#46 A 22-year-old man asks about HIV pre-exposure prophylaxis (PrEP) options. His friend takes “on-demand” PrEP and he asks your opinion.

What do you respond?

- A. On-demand PrEP cannot be recommended because it is not FDA-approved
- B. On-demand is not recommended in current guidelines
- C. On-demand PrEP has only been studied with tenofovir disoproxil fumarate (TDF)/emtricitabine (FTC)**
- D. On-demand PrEP has not been studied in men-who-have-sex-with-men (MSM)

2 of 2


3

BOARD REVIEW DAY 4

INFECTIOUS DISEASE

BOARD REVIEW

2025



#47 A 16-yr old male high school student from suburban Alexandria, Virginia presented with episodes during the past three months when he felt like his heart was “bursting from his chest” when he was doing push-ups in gym class.

This went away promptly when he stopped exercising. He said it didn’t feel like skipped beats and was not associated with chest pain or dyspnea.

He grew up in Iran, but his family has moved the USA four years previously. On exam, he was afebrile and appeared healthy.

A grade 3 systolic and diastolic murmur was heard at the left sternal border. Echocardiogram found mitral stenosis and regurgitation, with a thickened mitral valve without vegetations and an enlarged left atrium.

1 of 3

4

BOARD REVIEW DAY 4

INFECTIOUS DISEASE BOARD REVIEW 2025

#47 EKG showed first degree heart block with a PR interval of 300 msec and no extrasystoles.
Routine chemistries and CBC were normal but CRP and ESR were elevated.
Which of these tests would be the most helpful in diagnosis?
A. Anticardiolipin IgG
B. Anti dsDNA
C. Anti Coxiella burnetii phase 2 IgG
D. Anti streptococcal DNase B
E. PCR on blood for Tropheryma whippiei

2 of 3

5

BOARD REVIEW DAY 4

INFECTIOUS DISEASE BOARD REVIEW 2025

#47 EKG showed first degree heart block with a PR interval of 300 msec and no extrasystoles.
Routine chemistries and CBC were normal but CRP and ESR were elevated.
Which of these tests would be the most helpful in diagnosis?
A. Anticardiolipin IgG
B. Anti dsDNA
C. Anti Coxiella burnetii phase 2 IgG
D. Anti streptococcal DNase B**
E. PCR on blood for Tropheryma whippiei

3 of 3

6

BOARD REVIEW DAY 4

INFECTIOUS DISEASE BOARD REVIEW 2025

#48 A 35-year-old woman presents to her primary care clinic with 6 weeks of cough, shortness of breath, and new skin lesions. She has no fever or weight loss. She is found to be HIV positive (CD4 count 150 cells/mm3 and HIV viral load 500,000 copies/mL).
She has lived in Delaware all of her life, with no long-distance travel. She has no unusual pets or exposures although she does admit to commercial sex work over the past two decades.
On physical examination she has multiple purple-red skin lesions on her face, trunk and extremities.
Her PaO2 on room air is 95% and her routine blood count and chemistries are normal.

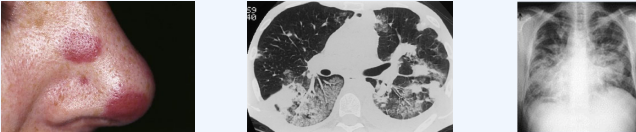
1 of 4

7

BOARD REVIEW DAY 4

INFECTIOUS DISEASE BOARD REVIEW 2025

#48 Her chest x-ray is strikingly abnormal, as is her chest CT scan which is read as showing reticular nodules, consolidation, and effusions consistent with Kaposi sarcoma.



<https://phil.cdc.gov/Details.aspx?pid=6436>
Serologic studies for cryptococcus and histoplasma are negative, and she is IGRA negative.
Induced sputum studies are negative for PCP (PCR), routine culture, and mycobacterial and fungal cultures at 7 days.

2 of 4

8

BOARD REVIEW DAY 4

INFECTIONSDISEASE
BOARD REVIEW
2025

#48 How would you evaluate the cause of the pulmonary and endobronchial lesions before starting treatment for Kaposi sarcoma?

- A. Bronchoalveolar lavage
- B. Transbronchial biopsy
- C. Percutaneous needle biopsy of lung
- D. Nothing further

3 of 4

9

BOARD REVIEW DAY 4

INFECTIONSDISEASE
BOARD REVIEW
2025

#48 How would you evaluate the cause of the pulmonary and endobronchial lesions before starting treatment for Kaposi sarcoma?

- A. Bronchoalveolar lavage**
- B. Transbronchial biopsy
- C. Percutaneous needle biopsy of lung
- D. Nothing further

4 of 4

10

BOARD REVIEW DAY 4

INFECTIONSDISEASE
BOARD REVIEW
2025

#49 A 21-year-old patient with HIV on bicitgravir/tenofovir alafenamide/emtricitabine (BIC/TAF/FTC) and history of adherence challenges resulting in intermittent low-level viremia presents to clinic. When lab results return, viral load has increased to 34,000 c/mL. The patient admits to discontinuing therapy because “he feels fine.”. Genotypic resistance testing is ordered.

How soon after discontinuation of antiretroviral therapy should resistance testing ideally be performed in order to detect drug resistance mutations?

- A. Within 4 weeks
- B. Within 3 months
- C. Within 6 months
- D. Within 12-18 months

1 of 2

11

BOARD REVIEW DAY 4

INFECTIONSDISEASE
BOARD REVIEW
2025

#49 A 21-year-old patient with HIV on bicitgravir/tenofovir alafenamide/emtricitabine (BIC/TAF/FTC) and history of adherence challenges resulting in intermittent low-level viremia presents to clinic. When lab results return, viral load has increased to 34,000 c/mL. The patient admits to discontinuing therapy because “he feels fine.”. Genotypic resistance testing is ordered.

How soon after discontinuation of antiretroviral therapy should resistance testing ideally be performed in order to detect drug resistance mutations?

- A. Within 4 weeks**
- B. Within 3 months
- C. Within 6 months
- D. Within 12-18 months

2 of 2

12

BOARD REVIEW DAY 4

INFECTIONSDISEASE
BOARD REVIEW
2025

#50

A 50-year-old male has HIV (CD4=40 cells/uL and HIV viral load=600,000 copies/uL) has central nervous system toxoplasmosis documented by a compatible CT of the head and a positive CSF PCR for toxoplasma.

The patient also has cryptosporidiosis with 6 stools per day plus considerable nausea and thus has limited food intake.

The pharmacy cannot obtain sulfadiazine or pyrimethamine.

What would be the best option for toxoplasmosis therapy?

- A. Atovaquone
- B. Clindamycin plus Primaquine
- C. Trimethoprim-Sulfamethoxazole
- D. Azithromycin plus Doxycycline
- E. Nitazoxanide

1 of 2

13

BOARD REVIEW DAY 4

INFECTIONSDISEASE
BOARD REVIEW
2025

#50

A 50-year-old male has HIV (CD4=40 cells/uL and HIV viral load=600,000 copies/uL) has central nervous system toxoplasmosis documented by a compatible CT of the head and a positive CSF PCR for toxoplasma.

The patient also has cryptosporidiosis with 6 stools per day plus considerable nausea and thus has limited food intake.

The pharmacy cannot obtain sulfadiazine or pyrimethamine.

What would be the best option for toxoplasmosis therapy?

- A. Atovaquone
- B. Clindamycin plus Primaquine
- C. Trimethoprim-Sulfamethoxazole**
- D. Azithromycin plus Doxycycline
- E. Nitazoxanide

2 of 2

14

BOARD REVIEW DAY 4

INFECTIONSDISEASE
BOARD REVIEW
2025

#51

Which of the following is correct regarding primary prophylaxis for disseminated mycobacterium avium complex (MAC) disease?

- A. Initiate primary prophylaxis if CD4 count is <50 cells/mm³
- B. Initiate primary prophylaxis if CD4 count is <100 cells/mm³
- C. Initiate primary prophylaxis if CD4 count is <200 cells/mm³
- D. Primary prophylaxis is not recommended for people with HIV who immediately initiate antiretroviral therapy

1 of 2

15

BOARD REVIEW DAY 4

INFECTIONSDISEASE
BOARD REVIEW
2025

#51

Which of the following is correct regarding primary prophylaxis for disseminated mycobacterium avium complex (MAC) disease?

- A. Initiate primary prophylaxis if CD4 count is <50 cells/mm³
- B. Initiate primary prophylaxis if CD4 count is <100 cells/mm³
- C. Initiate primary prophylaxis if CD4 count is <200 cells/mm³
- D. Primary prophylaxis is not recommended for people with HIV who immediately initiate antiretroviral therapy**

2 of 2

16

BOARD REVIEW DAY 4

INFECTIOUS DISEASE BOARD REVIEW 2025

#52

A 72-year-old male living in a rural area of Southern New York State was admitted to the hospital in June with a five-day history of nausea, vomiting, headache, fever, somnolence, and confusion.

On examination, he had a temperature of 39°C, was oriented only to the person, had weakness in the right lower extremity, a faint maculopapular rash on his upper chest and back, and a right facial droop.

Routine laboratory tests were normal. LP: showed 108 WBC/mm³ with 31% PMN, protein 113 mg/dl, and glucose 67 mg/dl. IgM serology for West Nile Virus on the CSF and serum was negative, as was the PCR for herpes simplex and West Nile virus.

MRI showed diffuse hyperintensity in the left basal ganglia on T2 and FLAIR imaging. He became progressively obtunded, requiring intubation for airway protection.

1 of 3

17

BOARD REVIEW DAY 4

INFECTIOUS DISEASE BOARD REVIEW 2025

#52

According to his wife, he had been in good health and had returned two weeks before his illness from a camping trip with his family in a lake area in New Hampshire.

She said her husband had been concerned about finding a few ticks on his body while camping but had removed them the day he thought he had acquired them.

Which of the following agents is the most likely cause of this illness?

- A. Varicella Zoster virus
- B. Herpes simplex virus
- C. Zika virus
- D. Powassan virus
- E. Enterovirus D68

2 of 3

18

BOARD REVIEW DAY 4

INFECTIOUS DISEASE BOARD REVIEW 2025

#52

According to his wife, he had been in good health and had returned two weeks before his illness from a camping trip with his family in a lake area in New Hampshire.

She said her husband had been concerned about finding a few ticks on his body while camping but had removed them the day he thought he had acquired them.

Which of the following agents is the most likely cause of this illness?

- A. Varicella Zoster virus
- B. Herpes simplex virus
- C. Zika virus
- D. Powassan virus**
- E. Enterovirus D68

3 of 3

19

BOARD REVIEW DAY 4

INFECTIOUS DISEASE BOARD REVIEW 2025

#53

Which of the following has demonstrated the greatest efficacy for HIV pre-exposure prophylaxis in women?

- A. Daily tenofovir alafenamide/emtricitabine
- B. On-demand tenofovir disoproxil fumarate/emtricitabine (2-1-1 dosing)
- C. Monthly intramuscular cabotegravir
- D. Every 2-month intramuscular cabotegravir

1 of 2

20

BOARD REVIEW DAY 4
INFECTIOUS DISEASE BOARD REVIEW 2025

#53 Which of the following has demonstrated the greatest efficacy for HIV pre-exposure prophylaxis in women?

A. Daily tenofovir alafenamide/emtricitabine
B. On-demand tenofovir disoproxil fumarate/emtricitabine (2-1-1 dosing)
C. Monthly intramuscular cabotegravir
D. Every 2-month intramuscular cabotegravir**

2 of 2

21

BOARD REVIEW DAY 4
INFECTIOUS DISEASE BOARD REVIEW 2025

#54 A 49-year-old previously healthy female is referred to the ID clinic with 1-month of left sided neck swelling.

Two weeks before the onset of symptoms, she found a tick embedded behind her left ear. She removed this without difficulty but developed an ulcerated area at the site of attachment (see arrow below).

Subsequently she developed left posterior auricular and posterior chain lymphadenopathy. A lymph node biopsy showed inflammatory changes with negative AFB and fungal stains.

She denies fevers or sore throat but does endorse fatigue.

1 of 4


22

BOARD REVIEW DAY 4
INFECTIOUS DISEASE BOARD REVIEW 2025

#54 She lives in a suburb of Nashville and works as a publicist. She has a pet dog and two cats, all of whom are healthy. She is an avid gardener and notes both rabbits and deer have been eating the planted vegetables. She denies sick contacts.

Physical exam shows the lesions in the photo shown here.

Lab tests including CBC diff and CMP are both within normal limits.



2 of 4

23

BOARD REVIEW DAY 4
INFECTIOUS DISEASE BOARD REVIEW 2025

#54 What is the most likely cause of this patient's symptoms?

A. *Bartonella henselae*
B. Kikuchi syndrome
C. *Ehrlichia chaffeensis*
D. *Yersinia pestis*
E. *Francisella tularensis*

3 of 4

24

BOARD REVIEW DAY 4

INFECTIONSDISEASE
BOARD REVIEW
2025

#54 What is the most likely cause of this patient's symptoms?

A. *Bartonella henselae*

B. Kikuchi syndrome

C. *Ehrlichia chaffeensis*

D. *Yersinia pestis*

E. *Francisella tularensis***

4 of 4

25

BOARD REVIEW DAY 4

INFECTIONSDISEASE
BOARD REVIEW
2025

#55 A person with HIV who takes antiretroviral therapy as prescribed and achieves and maintains viral suppression will not transmit HIV to their sex partners (Undetectable = Untransmittable).

Viral suppression in the context of treatment as prevention is defined by the Centers for Disease Control and Prevention as?

A. HIV-RNA level below the lower limit of detection of available assay

B. HIV-RNA level < 50 copies/mL

C. HIV-RNA level < 200 copies/mL

D. HIV-RNA level < 1000 copies/mL

1 of 2

26

BOARD REVIEW DAY 4

INFECTIONSDISEASE
BOARD REVIEW
2025

#55 A person with HIV who takes antiretroviral therapy as prescribed and achieves and maintains viral suppression will not transmit HIV to their sex partners (Undetectable = Untransmittable).

Viral suppression in the context of treatment as prevention is defined by the Centers for Disease Control and Prevention as?

A. HIV-RNA level below the lower limit of detection of available assay

B. HIV-RNA level < 50 copies/mL

C. HIV-RNA level < 200 copies/mL**

D. HIV-RNA level < 1000 copies/mL

2 of 2

27

BOARD REVIEW DAY 4

INFECTIONSDISEASE
BOARD REVIEW
2025

#56 A 24-year-old man newly diagnosed with HIV presents to care for rapid initiation of antiretroviral therapy. The patient previously received pre-exposure prophylaxis (PrEP) with intramuscular cabotegravir x 1 dose which was discontinued due to injection site reaction with subsequent use of tenofovir disoproxil fumarate/emtricitabine (TDF/FTC) for PrEP. Baseline labs, including hepatitis B serologies and HIV resistance testing, are pending.

Which of the following is an appropriate choice for rapid ART initiation?

A. Bictegravir/Tenofovir Alafenamide/Emtricitabine

B. Darunavir/Cobicistat/Tenofovir Alafenamide/Emtricitabine

C. Dolutegravir/Lamivudine

D. Doravirine/Tenofovir Disoproxil Fumarate/Emtricitabine

1 of 2

28

BOARD REVIEW DAY 4

INFECTIONSDISEASE
BOARD REVIEW
2025

#56

A 24-year-old man newly diagnosed with HIV presents to care for rapid initiation of antiretroviral therapy. The patient previously received pre-exposure prophylaxis (PrEP) with intramuscular cabotegravir x 1 dose which was discontinued due to injection site reaction with subsequent use of tenofovir disoproxil fumarate/emtricitabine (TDF/FTC) for PrEP. Baseline labs, including hepatitis B serologies and HIV resistance testing, are pending.

Which of the following is an appropriate choice for rapid ART initiation?

A. Bictegravir/Tenofovir Alafenamide/Emtricitabine
B. Darunavir/Cobicistat/Tenofovir Alafenamide/Emtricitabine**
C. Dolutegravir/Lamivudine
D. Doravirine/Tenofovir Disoproxil Fumarate/Emtricitabine

2 of 2

29

BOARD REVIEW DAY 4

INFECTIONSDISEASE
BOARD REVIEW
2025

#57

A 44-year-old male has noted about ten small skin and oral lesions appearing and growing slowly over several months. He feels well and has no other complaints. He is afebrile.

He admits to multiple same sex partners over the past 20 years. He was aware of his HIV diagnosis several years ago but had never wanted to pursue therapy.

His physical examination and chest Xray are normal other than the skin and mucosal lesions.

Laboratory values are remarkable for positive HIV serology, CD4 count 400 cells/mm3, HIV viral load of 400,000 copies/mL. His routine hematology and chemistry blood work are normal.

1 of 3

30

BOARD REVIEW DAY 4


INFECTIONSDISEASE
BOARD REVIEW
2025

#57

Some of his lesions are shown here:

What diagnostic test(s) should you order to establish the cause and determine the therapy of these skin and mucosal lesions?

A. Skin biopsy only
B. Skin and mucosal biopsies
C. Skin biopsy and HHV 8 serology
D. Skin biopsy, serum HHV 8 PCR, and serum HHV 8 serology
E. No further test: the diagnosis of Kaposi sarcoma can be made clinically in this case



<https://phill.cdc.gov/Details.aspx?pid=6436>

2 of 3

31

BOARD REVIEW DAY 4


INFECTIONSDISEASE
BOARD REVIEW
2025

#57

Some of his lesions are shown here:

What diagnostic test(s) should you order to establish the cause and determine the therapy of these skin and mucosal lesions?

A. Skin biopsy only**
B. Skin and mucosal biopsies
C. Skin biopsy and HHV 8 serology
D. Skin biopsy, serum HHV 8 PCR, and serum HHV 8 serology
E. No further test: the diagnosis of Kaposi sarcoma can be made clinically in this case



<https://phill.cdc.gov/Details.aspx?pid=6436>

3 of 3

32

BOARD REVIEW DAY 4
INFECTION DISEASE BOARD REVIEW
2025

#58 A 36-year-old male with HIV, well controlled on antiretroviral therapy (TDF/FTC/DTG) for the last two years, presents to establish care at a new clinic.

He is requesting to switch to long-acting injectable therapy with Cabotegravir / Rilpivirine as a friend recently started this treatment with a high degree of satisfaction.

The patient's treatment history includes TDF/FTC/EFV which was discontinued due to poor tolerance and intermittent adherence; subsequent genotyping revealed a K103N mutation.

Other medical history includes methamphetamine use disorder (currently in remission) and depression (treated with escitalopram).

1 of 4

33

BOARD REVIEW DAY 4
INFECTION DISEASE BOARD REVIEW
2025

#58 Recent labs are as follows:

- HIV viral load < 20 copies per mL
- CD4+ T cell count 452 cells per cubic mL
- RPR non-reactive
- Hepatitis B surface antibody negative
- Hepatitis B core IgG positive
- Hepatitis B surface antigen positive
- Hepatitis B DNA viral load < 10 IU / mL
- Hepatitis C IgG negative
- Complete blood count, basic metabolic panel and liver function testing are all within normal limits.

2 of 4

34

BOARD REVIEW DAY 4
INFECTION DISEASE BOARD REVIEW
2025

#58 For this patient, which of the following would preclude switching to long-acting injectable therapy with cabotegravir /rilpivirine (LA CAB/RPV)?

A. History of treatment failure with TDF/FTC/EFV
B. K103N mutation
C. Current treatment with escitalopram
D. Positive Hepatitis B surface antigen
E. History of methamphetamine use disorder

3 of 4

35

BOARD REVIEW DAY 4
INFECTION DISEASE BOARD REVIEW
2025

#58 For this patient, which of the following would preclude switching to long-acting injectable therapy with cabotegravir /rilpivirine (LA CAB/RPV)?

A. History of treatment failure with TDF/FTC/EFV
B. K103N mutation
C. Current treatment with escitalopram
D. Positive Hepatitis B surface antigen**
E. History of methamphetamine use disorder

4 of 4

36

BOARD REVIEW DAY 4
INFECTION DISEASE BOARD REVIEW
2025

#59 A 31-year-old woman is brought to the emergency department by her husband for fever and neurological symptoms.
She was completely well until 3 days earlier, when she felt nauseated and vomited twice.
During the next two days she had fever, felt “achy,” developed a headache, and continued to have nausea and vomiting.
Upon awakening this morning, she complained of double vision, and her husband noted her eyes “weren’t looking in the same place.”
In the emergency room, she was found to have a temperature of 102.4°F. There was no rash. She had mild nuchal rigidity, right 6th cranial nerve palsy, and a sensory deficit over most of the left side of her body.

1 of 3

37

BOARD REVIEW DAY 4
INFECTION DISEASE BOARD REVIEW
2025

#59 Her gait was very unsteady. The rest of the exam was unremarkable.
An MRI of the head demonstrated inflammation of the pons and medulla.
Which one of the following organisms is the most likely cause of her illness?
A. Streptococcus pneumoniae
B. Nocardia nova
C. Mycobacterium tuberculosis
D. Listeria monocytogenes
E. Cryptococcus neoformans

2 of 3

38

BOARD REVIEW DAY 4
INFECTION DISEASE BOARD REVIEW
2025

#59 Her gait was very unsteady. The rest of the exam was unremarkable.
An MRI of the head demonstrated inflammation of the pons and medulla.
Which one of the following organisms is the most likely cause of her illness?
A. Streptococcus pneumoniae
B. Nocardia nova
C. Mycobacterium tuberculosis
D. Listeria monocytogenes**
E. Cryptococcus neoformans

3 of 3

39

BOARD REVIEW DAY 4
INFECTION DISEASE BOARD REVIEW
2025

#60 A woman with HIV, a history of multiple antiretroviral regimens, and prior virologic failures is currently well controlled on a regimen of dolutegravir (DTG) once daily plus darunavir/cobicistat/tenofovir alafenamide/emtricitabine (DRV/c/TAF/FTC) once daily. She is now pregnant and presents for follow up.
Which of the following statements is correct?
A. The patient is well controlled on the current regimen; continue standard treatment and monitoring measures
B. Tenofovir alafenamide is not recommended in pregnant individuals
C. Darunavir/cobicistat is not recommended in pregnant individuals
D. Darunavir/cobicistat dose should be increased from once daily to twice daily

1 of 2

40

BOARD REVIEW DAY 4



#60 A woman with HIV, a history of multiple antiretroviral regimens, and prior virologic failures is currently well controlled on a regimen of dolutegravir (DTG) once daily plus darunavir/cobicistat/tenofovir alafenamide/emtricitabine (DRV/c/TAF/FTC) once daily. She is now pregnant and presents for follow up.

Which of the following statements is correct?

- A. The patient is well controlled on the current regimen; continue standard treatment and monitoring measures
- B. Tenofovir alafenamide is not recommended in pregnant individuals
- C. Darunavir/cobicistat is not recommended in pregnant individuals****
- D. Darunavir/cobicistat dose should be increased from once daily to twice daily

2 of 2