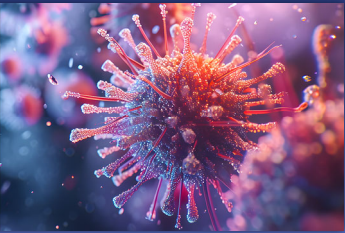


IDBR

INFECTIOUS DISEASE BOARD REVIEW

AUGUST 16-20, 2025



Board Review: Day 2


Moderator: David Aronoff, MD
Faculty: Drs. Boucher, Kotton, Mitre, Platts-Mills, and Thomas

7/18/2025

1

BOARD REVIEW DAY 2

INFECTIOUS DISEASE BOARD REVIEW 2025



#16 A previously healthy man is referred for poor response of his community-acquired pneumonia to azithromycin and ceftriaxone.

He remains febrile on day 3 of hospitalization but is clinically stable and not intubated. T

he admission respiratory panel had been positive only for *Mycoplasma pneumoniae* and negative for other respiratory viruses.


Urine antigen for pneumococci and *Legionella* were negative and admission sputum culture had been reported as normal flora.

1 of 3

2

BOARD REVIEW DAY 2

INFECTIOUS DISEASE BOARD REVIEW 2025



#16 What might management include?


- A. Change azithromycin to doxycycline
- B. Change ceftriaxone to meropenem
- C. Add vancomycin
- D. Change ceftriaxone to ertapenem
- E. Repeat NP swab for SARS-CoV-2 (COVID-19)

2 of 3

3

BOARD REVIEW DAY 2

INFECTIOUS DISEASE BOARD REVIEW 2025



#16 What might management include?


- A. Change azithromycin to doxycycline**
- B. Change ceftriaxone to meropenem
- C. Add vancomycin
- D. Change ceftriaxone to ertapenem
- E. Repeat NP swab for SARS-CoV-2 (COVID-19)

3 of 3

4

BOARD REVIEW DAY 2

INFECTIOUS DISEASE BOARD REVIEW 2025



#17 A 60-yr old woman has had repeated episodes of erysipelas in her left arm after breast surgery and radiation for cancer had caused substantial lymphedema in that arm. She has inquired whether you might prescribe something she could take to prevent these infections. She has no history of drug allergies or intolerance.

Among the options you discuss with her might include taking which of these antibiotics prophylactically?


A. Trimethoprim-sulfamethoxazole
B. Penicillin V
C. Clindamycin
D. Amoxicillin-clavulanate
E. Erythromycin

1 of 2

5

BOARD REVIEW DAY 2

INFECTIOUS DISEASE BOARD REVIEW 2025



#17 A 60-yr old woman has had repeated episodes of erysipelas in her left arm after breast surgery and radiation for cancer had caused substantial lymphedema in that arm. She has inquired whether you might prescribe something she could take to prevent these infections. She has no history of drug allergies or intolerance.

Among the options you discuss with her might include taking which of these antibiotics prophylactically?


A. Trimethoprim-sulfamethoxazole
B. Penicillin V**
C. Clindamycin
D. Amoxicillin-clavulanate
E. Erythromycin

2 of 2

6

BOARD REVIEW DAY 2

INFECTIOUS DISEASE BOARD REVIEW 2025



#18 Based on randomized controlled trials, Letermovir was approved by the U.S. FDA for prophylaxis of cytomegalovirus (CMV) in adult CMV-seropositive recipients [R+] of allogeneic hematopoietic stem cell transplants and adult CMV seronegative kidney transplant recipients from CMV R+ donors.

Compared with Valganciclovir, which of the following is true about Letermovir?


A. Is associated with a higher risk of leukopenia
B. Requires dose adjustment for renal impairment
C. Does not require dose adjustment when administered with cyclosporin
D. Is not active against other herpes viruses besides CMV, including herpes simplex virus (HSV) or varicella zoster virus (VZV)

1 of 2

7

BOARD REVIEW DAY 2

INFECTIOUS DISEASE BOARD REVIEW 2025



#18 Based on randomized controlled trials, Letermovir was approved by the U.S. FDA for prophylaxis of cytomegalovirus (CMV) in adult CMV-seropositive recipients [R+] of allogeneic hematopoietic stem cell transplants and adult CMV seronegative kidney transplant recipients from CMV R+ donors.

Compared with Valganciclovir, which of the following is true about Letermovir?

A. Is associated with a higher risk of leukopenia
B. Requires dose adjustment for renal impairment
C. Does not require dose adjustment when administered with cyclosporin
D. Is not active against other herpes viruses besides CMV, including herpes simplex virus (HSV) or varicella zoster virus (VZV)**

2 of 2

8

BOARD REVIEW DAY 2

INFECTIOUS DISEASE BOARD REVIEW 2025

#19

A 52-yr old man vacationing in Cancun, Mexico developed frequent watery stools (about 5/24 hours). This was interfering with his snorkeling and other vacation activities but not causing abdominal pain, fever or bloody diarrhea. He has only a few days of vacation left and wants his diarrhea to be over. He takes simvastatin and clopidogrel.

In addition to prescribing loperamide and/or bismuth subsalicylate, which of these other drugs might be reasonable to add?

- A. Ciprofloxacin
- B. Rifaximin
- C. Rifampin
- D. Azithromycin
- E. Doxycycline

1 of 2

9

BOARD REVIEW DAY 2

INFECTIOUS DISEASE BOARD REVIEW 2025

#19

A 52-yr old man vacationing in Cancun, Mexico developed frequent watery stools (about 5/24 hours). This was interfering with his snorkeling and other vacation activities but not causing abdominal pain, fever or bloody diarrhea. He has only a few days of vacation left and wants his diarrhea to be over. He takes simvastatin and clopidogrel.

In addition to prescribing loperamide and/or bismuth subsalicylate, which of these other drugs might be reasonable to add?

- A. Ciprofloxacin
- B. Rifaximin**
- C. Rifampin
- D. Azithromycin
- E. Doxycycline

2 of 2

10

BOARD REVIEW DAY 2

INFECTIOUS DISEASE BOARD REVIEW 2025

#20

56-year-old man presents for treatment of HCV infection. He has a history of type 2 diabetes mellitus, significant coronary disease, and HTN.

He is taking atorvastatin, metformin, and hydrochlorothiazide.

He is HIV negative, HBsAg negative. His HCV RNA is 3.2 log IU/ml. FIB-4 is 5.6 (high risk for advanced fibrosis).

Transient elastography 28 kPa (cirrhosis).

Creatine clearance is 84.

1 of 3

11

BOARD REVIEW DAY 2

INFECTIOUS DISEASE BOARD REVIEW 2025

#20

Ultrasound of RUQ is negative for HCC but shows ascites. UGI shows several varices and the performing gastroenterologist says it is too early to list for transplant.

Which is the best option?

- A. Glecaprevir and pibrentasvir for 8 weeks
- B. Glecaprevir and pibrentasvir for 16 weeks
- C. Sofosbuvir and velpatasvir for 12 weeks
- D. Sofosbuvir and velpatasvir for 24 weeks
- E. Sofosbuvir alone for 24 weeks

2 of 3

12

BOARD REVIEW DAY 2
INFECTIOUS DISEASE BOARD REVIEW 2025

#20 Ultrasound of RUQ is negative for HCC but shows ascites. UGI shows several varices and the performing gastroenterologist says it is too early to list for transplant.

Which is the best option?

A. Glecaprevir and pibrentasvir for 8 weeks
B. Glecaprevir and pibrentasvir for 16 weeks
C. Sofosbuvir and velpatasvir for 12 weeks
D. Sofosbuvir and velpatasvir for 24 weeks**
E. Sofosbuvir alone for 24 weeks

3 of 3

13

BOARD REVIEW DAY 2
INFECTIOUS DISEASE BOARD REVIEW 2025

#21 A35-year-old Illinois resident, in prior good health, presented to the emergency room with high fever, beginning a week after returning from a 5-day meeting in Ghana.

He was found to have severe falciparum malaria, with a parasitemia of 7% and treated with intravenous artesunate, transitioned on day 2 to artemether-lumefantrine to finish a three course.

At discharge, his hemoglobin was 10 gm%, malaria smear negative for ring forms but contained a few gametocytes.

A week later he returned to the emergency room with fatigue and dyspnea.

1 of 3

14

BOARD REVIEW DAY 2
INFECTIOUS DISEASE BOARD REVIEW 2025

#21 Physical examination was normal, though with BP slightly low for him (100/50) and pulse 92. Hemoglobin was 4.9 gm%, reticulocytes 12%, haptoglobin undetectable, total bilirubin 1.4 gm/dl, and LDH 902 U/L. Rapid diagnostic test (RDT, Binax Now) for malaria was negative.

What is the probable reason for this condition?

A. Post-artesunate hemolysis
B. Autoimmune hemolytic anemia
C. G6PD deficiency reaction to lumefantrine
D. Babesia coinfection
E. False negative RDT, relapsed malaria

2 of 3

15

BOARD REVIEW DAY 2
INFECTIOUS DISEASE BOARD REVIEW 2025

#21 Physical examination was normal, though with BP slightly low for him (100/50) and pulse 92. Hemoglobin was 4.9 gm%, reticulocytes 12%, haptoglobin undetectable, total bilirubin 1.4 gm/dl, and LDH 902 U/L. Rapid diagnostic test (RDT, Binax Now) for malaria was negative.

What is the probable reason for this condition?

A. Post-artesunate hemolysis**
B. Autoimmune hemolytic anemia
C. G6PD deficiency reaction to lumefantrine
D. Babesia coinfection
E. False negative RDT, relapsed malaria

3 of 3

16

#22 A 58-year-old male presents with a four-month history of migratory polyarthralgia and then develops intermittent low-grade fevers, weight loss (15 lb), fatigue and chronic diarrhea with greasy and foul-smelling stools.

He lacks risk factors for HIV infection.

He was born and resides in a farming community in central California and is employed as an accountant.

His history is only notable for hypertension and hyperlipidemia, for which he has received medications since his mid-40s.

1 of 3

#22 On physical examination, he has diffuse abdominal tenderness, mild peripheral lymphadenopathy, and a skin exam wherein he appears tanned but has no recent sun exposure.

Laboratory testing reveals anemia, hypoalbuminemia, and elevated acute-phase reactants.

Which of the following tests would most likely lead to a diagnosis?

- A. Small bowel biopsy
- B. Serological testing for Celiac disease
- C. Multiplex molecular panel for enteric pathogens
- D. Stool ova and parasite collections x 3, including trichrome staining
- E. Large bowel biopsy

2 of 3

17

18

#22 On physical examination, he has diffuse abdominal tenderness, mild peripheral lymphadenopathy, and a skin exam wherein he appears tanned but has no recent sun exposure.

Laboratory testing reveals anemia, hypoalbuminemia, and elevated acute-phase reactants.

Which of the following tests would most likely lead to a diagnosis?

- A. Small bowel biopsy**
- B. Serological testing for Celiac disease
- C. Multiplex molecular panel for enteric pathogens
- D. Stool ova and parasite collections x 3, including trichrome staining
- E. Large bowel biopsy

3 of 3

#23 A 27-year-old man is referred by neurosurgery for assistance in management of a surgical complication.

Nine days previously the patient had undergone endolymphatic decompression for his refractory Meniere's syndrome. Preoperative cefazolin had been given.

The day following his left suboccipital craniotomy, CSF had been seen leaking from his operative wound. A lumbar drain was inserted, then removed 8 days later when CSF leakage had stopped.

The following morning the patient awoke with headache and temperature of 101 °F. He was alert and oriented but had nuchal rigidity. Lumbar puncture found an opening pressure of 380 mm, a CSF WBC of 9,500/μL with 90% neutrophils, glucose less than 5 mg/dL and protein 151 mg/dL.

1 of 3

19

20

BOARD REVIEW DAY 2

INFECTIOUS DISEASE BOARD REVIEW 2025

#23 Gram stain had Gram positive cocci in pairs and chains. Vancomycin, ceftazidime and metronidazole were begun. Head CT showed fluid in the left mastoid sinus but no other abnormalities. The next day the patient remained febrile, with a peripheral WBC of 14,200/ μ L. The microbiology laboratory said MALDI-TOF on early growth from the CSF indicated *Enterococcus faecium*.

What would be the most helpful change in his antibiotics?

A. Increase vancomycin from 2 to 4 gm/24 hr

B. Change ceftazidime and metronidazole to piperacillin-tazobactam

C. Change vancomycin to daptomycin

D. Change vancomycin to linezolid

E. Change vancomycin to dalbavancin

2 of 3

21

BOARD REVIEW DAY 2

INFECTIOUS DISEASE BOARD REVIEW 2025

#23 Gram stain had Gram positive cocci in pairs and chains. Vancomycin, ceftazidime and metronidazole were begun. Head CT showed fluid in the left mastoid sinus but no other abnormalities. The next day the patient remained febrile, with a peripheral WBC of 14,200/ μ L. The microbiology laboratory said MALDI-TOF on early growth from the CSF indicated *Enterococcus faecium*.

What would be the most helpful change in his antibiotics?

A. Increase vancomycin from 2 to 4 gm/24 hr

B. Change ceftazidime and metronidazole to piperacillin-tazobactam

C. Change vancomycin to daptomycin

D. Change vancomycin to linezolid**

E. Change vancomycin to dalbavancin

3 of 3

22

BOARD REVIEW DAY 2


INFECTIOUS DISEASE BOARD REVIEW 2025

#24 A 32-year-old female with HIV infection (VL=100k, and a CD4 count below 10 cells/mm³) has failed all available ART regimens.

Her mother brings her to the clinic because of confusion for 1-2 weeks. She is afebrile, oriented x 1, and slow to respond.

She has nystagmus and CN VI palsy on the right.

The contrast enhanced MRI image shown is read as showing ventriculitis, i.e., inflammation of the ependymal lining of the lateral cerebral ventricles.



1 of 3

23

BOARD REVIEW DAY 2

INFECTIOUS DISEASE BOARD REVIEW 2025

#24 Which PCR of CSF would most likely provide the most likely diagnosis?

A. JC

B. EBV

C. CMV

D. HHV6

E. HHV8

2 of 3

24

BOARD REVIEW DAY 2

INFECTIONSDISEASE
BOARD REVIEW
2025

#24 Which PCR of CSF would most likely provide the most likely diagnosis?

- A. JC
- B. EBV
- C. CMV**
- D. HHV6
- E. HHV8

3 of 3

25

BOARD REVIEW DAY 2

INFECTIONSDISEASE
BOARD REVIEW
2025

#25 A 21year old undergraduate student is admitted to the hospital with 2 days of fever and diarrhea, with 12 bowel movements per day.

She presented after an episode of hematochezia. She denies travel outside of the US and no other students in her dorm are ill.

Physical exam is notable for fever to 38.7 C; other vital signs are within normal limits. The abdominal exam reveals diffuse tenderness but no rebound or peritoneal signs.

Labs are notable for a WBC of 15k, potassium of 2.4 and creatinine of 1.8.

1 of 3

26

BOARD REVIEW DAY 2

INFECTIONSDISEASE
BOARD REVIEW
2025

#25 Abdominal CT shows severe pancolitis most pronounced in the cecum and ascending colon.

A GI pathogen panel returns positive for Shiga-like toxin producing E. coli (STEC).

What is the most appropriate therapy for this patient?

- A. Supportive care; discontinue antibiotics
- B. Ciprofloxacin
- C. Azithromycin
- D. Piperacillin-tazobactam
- E. Loperamide

2 of 3

27

BOARD REVIEW DAY 2

INFECTIONSDISEASE
BOARD REVIEW
2025

#25 Abdominal CT shows severe pancolitis most pronounced in the cecum and ascending colon.

A GI pathogen panel returns positive for Shiga-like toxin producing E. coli (STEC).

What is the most appropriate therapy for this patient?

- A. Supportive care; discontinue antibiotics**
- B. Ciprofloxacin
- C. Azithromycin
- D. Piperacillin-tazobactam
- E. Loperamide

3 of 3

28

BOARD REVIEW DAY 2

INFECTIONSDISEASE
BOARD REVIEW
2025

#26 A 42-year-old man is referred for asymptomatic elevation of his liver function tests.

He underwent a living-related donor kidney transplantation 14 months earlier secondary to end-stage renal disease from uncontrolled hypertension (CMV D+/R-).

Six months after his transplant, his physicians noted an asymptomatic increase in aminotransferases, with aspartate aminotransferase (AST) 8 times the upper limit of normal (ULN), alanine aminotransferase (ALT) 6 x ULN, and gamma glutamyl transferase (GGT) 5 x ULN.

His total bilirubin was mildly elevated, and his alkaline phosphatase was normal.

1 of 5

29

BOARD REVIEW DAY 2

INFECTIONSDISEASE
BOARD REVIEW
2025

#26 The following were serologies were negative:

- Hepatitis A virus
- Hepatitis B virus (HBV) surface antigen
- Hepatitis C virus (HCV)
- Human immunodeficiency virus (HIV)- 1,2
- Epstein-Barr virus VCA IgM
- Herpes simplex virus 1 and 2 IgG
- Cytomegalovirus IgG

Also, negative or normal were:

- HBV DNA and HCV RNA were undetectable
- Liver autoimmunity panel was negative
- Abdominal ultrasound was normal

2 of 5

30

BOARD REVIEW DAY 2

INFECTIONSDISEASE
BOARD REVIEW
2025

#26 He denied alcohol consumption. He recently returned from living the past year in Germany and is an avid consumer of sausage.

His immunosuppressive regimen included tacrolimus, mycophenolate mofetil, and prednisolone.

His liver function tests have continued to be elevated over the past 9 months despite changes in his immunosuppressive regimen and antihypertensive medications.

3 of 5

31

BOARD REVIEW DAY 2

INFECTIONSDISEASE
BOARD REVIEW
2025

#26 His physical examination was unremarkable.

His BMI was 20 kg/m². No scleral icterus was noted, and no stigmata of cirrhosis were noted.

A liver biopsy demonstrated lobular hepatitis without fibrosis.

Which of the following entities is most likely responsible for his hepatitis?


- A. Coxiella burnetii
- B. Hepatitis D
- C. Hepatitis E
- D. Leptospira interrogans
- E. Non-alcoholic hepatosteatosis

4 of 5

32

BOARD REVIEW DAY 2

INFECTIOUS DISEASE BOARD REVIEW 2025



#26 His physical examination was unremarkable.
His BMI was 20 kg/m². No scleral icterus was noted, and no stigmata of cirrhosis were noted.
A liver biopsy demonstrated lobular hepatitis without fibrosis.
Which of the following entities is most likely responsible for his hepatitis?
A. Coxiella burnetii
B. Hepatitis D
C. Hepatitis E**
D. Leptospira interrogans
E. Non-alcoholic hepatosteatosis

5 of 5

33

BOARD REVIEW DAY 2

INFECTIOUS DISEASE BOARD REVIEW 2025




#27 A 29-year-old anthropologist presents with a chief complaint of recurrent soft tissue swellings.
He spends several months a year in tropical areas of Cameroon.
For the past three months he has noticed occasional focal swellings of his hands and forearms. These are about 4-6 cm in diameter, last for about a day and then spontaneously resolve.

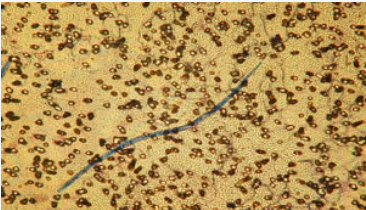
1 of 3

34

BOARD REVIEW DAY 2

INFECTIOUS DISEASE BOARD REVIEW 2025




#27 Giemsa stain of a filtered daytime blood sample shows the following.

Which of the following should be assessed prior to initiating therapy?
A. Lumbar puncture
B. Quantitative microfilaria count
C. Stool exam for ova and parasites
D. Brain MRI
E. Glucose-6-phosphate dehydrogenase level

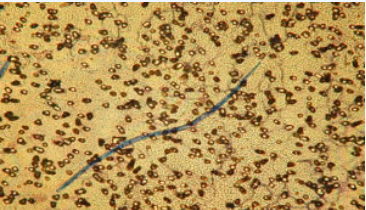
2 of 3

35

BOARD REVIEW DAY 2

INFECTIOUS DISEASE BOARD REVIEW 2025



#27 Giemsa stain of a filtered daytime blood sample shows the following.

Which of the following should be assessed prior to initiating therapy?
A. Lumbar puncture
B. Quantitative microfilaria count**
C. Stool exam for ova and parasites
D. Brain MRI
E. Glucose-6-phosphate dehydrogenase level

3 of 3

36

#28 An 18-year-old male is admitted with diarrhea, fever, and abdominal pain. Six weeks previously, he was diagnosed with parotiditis, and prescribed clindamycin for 14 days. Approximately 2 weeks later, he developed onset of frequent non-bloody liquid stools. *Clostridioides difficile* PCR and antigen returned positive, and he completed a 10-day course of oral fidaxomicin. He initially improved, but 5 days before admission started having recurrent liquid stools, decreased appetite, diffuse abdominal pain, and fever prompting hospital admission.

1 of 4

#28 On exam he is a thin, uncomfortable appearing man. Temperature is 102.4 F, BP is 102/68, HR is 95 and O2 saturation is 98% on room air. Abdominal exam is notable for diffuse discomfort to palpation, but no peritoneal signs. Bowel sounds are hyperactive. Labs include: WBC=10.9, Cr=0.68 Stool C diff PCR and antigen are both positive.

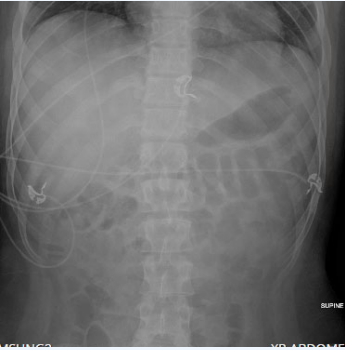
2 of 4

37

38

#28 Abdominal imaging shows dilated loops of bowel, but no evidence of ischemic colitis or megacolon. What is the best treatment option for this patient?

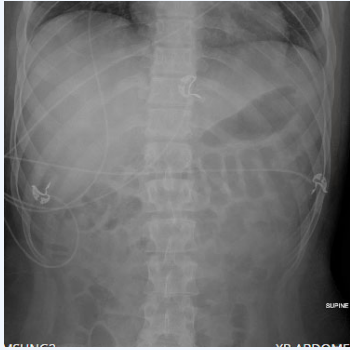
- A. Oral vancomycin and IV metronidazole
- B. Fecal microbiota transplant
- C. Oral vancomycin x 10 days followed by rifaximin for 20 days
- D. Oral Metronidazole x 14 days
- E. Fidaxomicin x 10 days



3 of 4

#28 Abdominal imaging shows dilated loops of bowel, but no evidence of ischemic colitis or megacolon. What is the best treatment option for this patient?

- A. Oral vancomycin and IV metronidazole
- B. Fecal microbiota transplant
- C. Oral vancomycin x 10 days followed by rifaximin for 20 days
- D. Oral Metronidazole x 14 days
- E. Fidaxomicin x 10 days**




4 of 4

39

40

BOARD REVIEW DAY 2

INFECTIONSDISEASE
BOARD REVIEW
2025




#29 A 32-year-old man in Chicago had the sudden onset of diarrhea with blood and mucus in the stool, accompanied by abdominal cramps and low-grade fever. Two days later his spouse developed the same symptoms. Neither had recent travel and no unusual food exposures other than the patient had eaten salmon at a business lunch with friends two days before onset. He was not aware of any illness in his business associates.

1 of 3

41

BOARD REVIEW DAY 2

INFECTIONSDISEASE
BOARD REVIEW
2025



#29 Which of the following is the likely pathogen?


A. Shigella sonnei
B. Salmonella typhimurium
C. Enterohemorrhagic E. coli
D. Norovirus
E. Vibrio parahaemolyticus

2 of 3

42

BOARD REVIEW DAY 2

INFECTIONSDISEASE
BOARD REVIEW
2025



#29 Which of the following is the likely pathogen?


A. Shigella sonnei**
B. Salmonella typhimurium
C. Enterohemorrhagic E. coli
D. Norovirus
E. Vibrio parahaemolyticus

3 of 3

43

BOARD REVIEW DAY 2

INFECTIONSDISEASE
BOARD REVIEW
2025




#30 A 34-year-old male construction worker from Los Angeles presents with fever and chills for the past two days. He had been healthy but while visiting his mother in Honduras had developed a fever and treated by a physician there for malaria with several days of a medicine he did not know. He had then been fine after returning two months ago. A rapid test in the emergency department is positive for malaria, not falciparum. A smear is sent to a reference laboratory for confirmation.

1 of 3

44

BOARD REVIEW DAY 2

INfectious Disease
BOARD REVIEW
2025



#30 Which of the following is a probable explanation for this situation?

A. False positive rapid test

B. Infection acquired in Los Angeles

C. Drug resistant malaria

D. Relapse of *P. vivax* malaria


E. Relapse of *P. ovale* malaria

2 of 3

45

BOARD REVIEW DAY 2

INfectious Disease
BOARD REVIEW
2025



#30 Which of the following is a probable explanation for this situation?

A. False positive rapid test

B. Infection acquired in Los Angeles

C. Drug resistant malaria

D. Relapse of *P. vivax* malaria**

E. Relapse of *P. ovale* malaria

3 of 3

46