



## Photo Opportunity I: Photos and Questions to Test Your Board Preparation

**Rajesh T. Gandhi, MD**  
 Massachusetts General Hospital  
 Professor of Medicine, Harvard Medical School  
 Boston, Massachusetts

8/5/2025


1



## Disclosures of Financial Relationships with Relevant Commercial Interests

- None

2



A Joint Project of the Massachusetts General Hospital Infectious Diseases Division and Microbiology Lab

- Cases are from an educational web-site:  
[www.idimages.org](http://www.idimages.org)

I acknowledge the contributors to the site for their case submissions and images.

3

### Question #1

50-year-old F developed ulcerated lesion on her left thumb which enlarged over several months despite several courses of antibiotics. She reported no sore throat, fever, chills, dyspnea or cough.

**SH:** Three months before, she travelled to Ecuador, where she stayed in an ecotourism hotel near a river. No known fresh- or salt-water exposure. Reported seeing several kinds of insects and receiving several bites. No known animal exposures or tick bites.

Contributed by Rojelio Mejia, MD

4

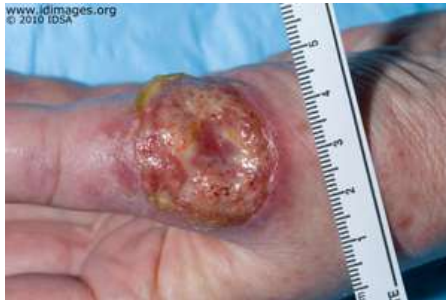## Question #1

**PE:** Patient appeared well;  
Temp 98.1

Raised ulcerated lesion on  
thumb with a violaceous border

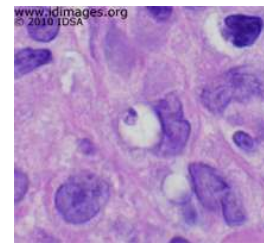
- A. Cutaneous leishmaniasis
- B. *Mycobacterium marinum*
- C. Sporotrichosis
- D. Pyoderma gangrenosum
- E. Tularemia

### Differential Diagnosis

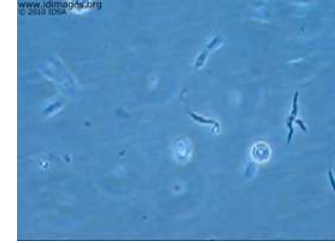


Skin biopsy showed amastigote, with kinetoplast in a vacuole.  
Culture of tissue from skin biopsy in Schneider's Media revealed promastigotes.

PCR of tissue: *Leishmania guyanensis*



Skin biopsy, H and E stain

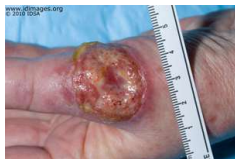

Culture of skin biopsy tissue in  
Schneider's medium

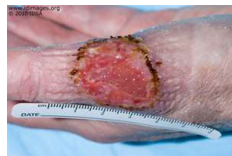5

6

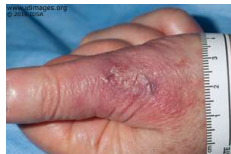## Treated with Liposomal Amphotericin



One week after treatment



Follow-up at 3 months



## Differential Diagnosis

- ***Mycobacterium marinum*:** patient did not have known fresh- or salt-water exposure; she did not have nodular lymphangitis
- **Sporotrichosis:** no known exposures to soil or thorn; she did not have nodular lymphangitis
- **Pyoderma gangrenosum:** patient did not have known inflammatory bowel disease or other underlying pre-disposing condition; ulcerative PG usually occurs on lower extremities, trunk
- **Tularemia:** no animal or tick exposure; no systemic symptoms; no adenopathy

7

8

## Question #2

- A man in his fifties presented with diarrhea, nausea, and vomiting of three days' duration
- He had recently been discharged from another hospital where he had received a one-week course of iv steroids for back pain
- **Past medical history:** spinal stenosis. Medication: prednisone
- **Social history:** Immigrated to the US from the Caribbean two decades ago; returned to visit one year ago
- **PE:** Temp 98.6. Mild epigastric tenderness. Remainder of exam normal

9

## Question #2

**Labs:** WBC 12,000 (neutrophils 43%, bands 38%, lymphocytes 10%). Creatinine 1.8

### Clinical course:

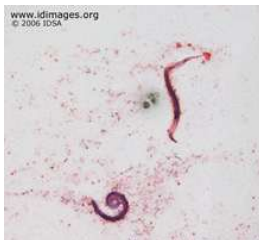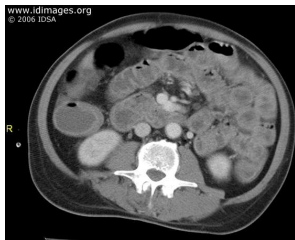- Patient received iv fluids because of concern for acute gastroenteritis and dehydration
- On hospital day 3, developed lethargy and fever (temp 102.4)
- Shortly thereafter, developed respiratory failure and *Klebsiella* was isolated from blood cultures (4/4 bottles) and cerebrospinal fluid

10

## Question #2

Abdominal CT:  
colonic wall inflammation

Gram stain of sputum



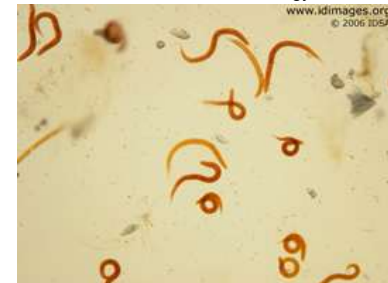- A. *Salmonella* bacteremia
- B. *Strongyloides* hyperinfection syndrome
- C. Amebic infection
- D. Ascariasis
- E. Fascioliasis

11

## Strongyloides Hyperinfection Ayndrome

- May occur during immunosuppression, even short courses of steroids
- Accelerated autoinfection
- Larval migration in GI tract, lungs, skin and, at times, other organs
- Migration of filariform larva may be associated with entry of enteric bacteria (eg, gram-negative sepsis, meningitis)
- Peripheral eosinophilia absent

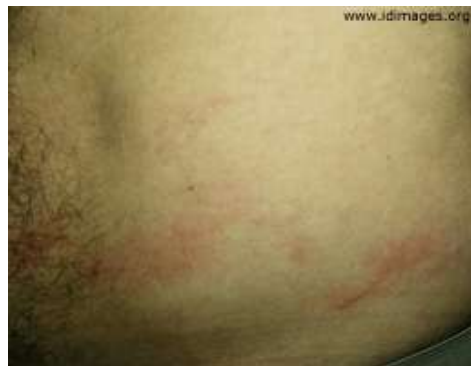Iodine stain of stool showed *Strongyloides*



12

## Larva currens: Cutaneous Strongyloidiasis

- Serpiginous urticarial rash caused by the dermal migration of filariform larvae
- Rash may move rapidly: 5-10 cm per hour



13

## Question #3

- 30-year-old woman with HIV (CD4 cell count 20, not on therapy) presented with gradual onset of word-finding difficulties, expressive aphasia and right upper extremity weakness over 4 weeks
- **Social history:** She lived in New England. No recent travel or known insect bites. Not sexually active.
- **PE:** On exam, she was afebrile. She had oral thrush. She had difficulty naming objects and right-sided weakness.
- **Studies:** WBC count of 2.2 (44% P, 45% L)

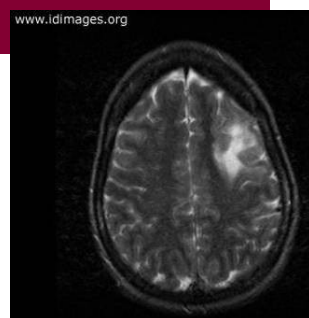
Contributed by Wendy Yeh, M.D.

14

## Question #3

**What is the most likely diagnosis?**

- A. An arbovirus
- B. A polyomavirus
- C. A herpes virus
- D. A spirochete
- E. A dematiaceous fungus



MRI: Abnormal T2 signal involving white matter, left fronto-parietal region.  
No enhancement, edema, mass effect

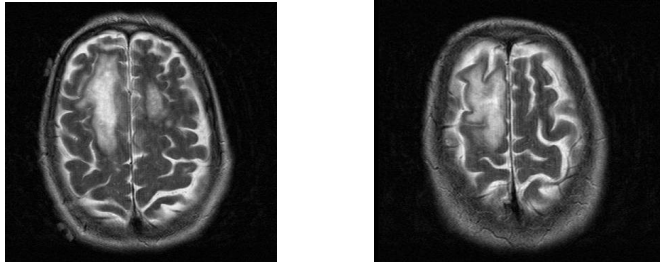
15

## Progressive Multifocal Leukoencephalopathy

- CSF JC virus positive
- Demyelinating disease of central nervous system caused by reactivation of JC virus, a polyoma virus
- Immunocompromised hosts (heme malignancy; HIV, natalizumab, rituximab)
- Rapidly progressive focal neurologic deficits, usually due to cerebral white matter disease
- Rx: reversal of immunodeficiency. In people with HIV: antiretroviral therapy

16

## PML



Contributed by Vince Marconi, M.D.

17

## Differential Diagnosis

- **Arbovirus, such as West Nile Virus:** Unlikely because of no confusion, headache, meningeal signs, paralysis.
- **Herpes virus, such as HSV:** temporal lobe.
- **Spirochetal infection, such as syphilis:** central nervous system gumma or stroke-like syndrome (meningovascular disease).
- **Dematiaceous fungus:** no risk factors (e.g. adjacent paranasal sinus infection, penetrating trauma); lack of enhancement of brain lesion on imaging.

18

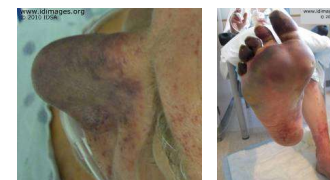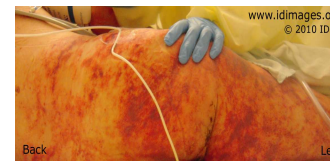
## Question #4

60-year-old M was well until day of admission when he developed lethargy and confusion. Over the course of the day, his hands and feet grew cold and numb, and he developed a rash.

**SH:** He lives in a rural area (mountain-lion territory) and drinks well-water. He has a history of alcohol use disorder. He rides horses and has dogs, one of whom bit him a few days before.

19

## Question #4



**PE:** Temp 102. Nonblanching, nonpalpable, purpuric patches on head, trunk, thighs; puncture wounds on dorsal aspect of hand; edema, cyanosis of nose

- E. coli* 0157:H7
- Yersinia pestis*
- Pasteurella*
- Capnocytophaga*
- Leptospirosis

20

## ***Capnocytophaga canimorsus***

- Blood cultures positive for *C. canimorsus*
- Facultative, fastidious gram-negative bacillus found in the mouth of dogs, cats.
- Risk factors: male sex, dog-bite, alcohol abuse, asplenia, immunosuppression
- Septicemia: 20-40% have a rash (maculopapular, progressing to purpura fulminans)

21

## **Differential diagnosis**

- ***E. coli* 0157:H7**: abdominal cramping, diarrhea; fever typically absent
- ***Yersinia pestis***: usually presents as bubonic plague, with regional lymphadenitis
- ***Pasteurella***: may follow cat or dog bit; usually presents with cellulitis; septicemia uncommon
- **Leptospirosis**: contact with urine or tissue of infected animals; in acute phase, pt may have conjunctival suffusion; purpura fulminans, as in this case, would be unusual

22

## **Question #5**

- Woman in her 40s with multiple sclerosis presented with several months of joint pain and swelling
- Subsequently developed confusion; hospitalized for evaluation

### Past medical history

- Hypogammaglobulinemia
- Intrauterine device complicated by peritoneal abscess several years prior to admission; cultures unrevealing

- Medications: prednisone 5 mg daily; rituximab

### Epidemiologic history

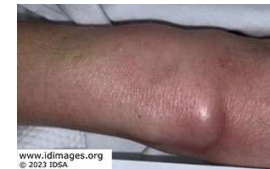- Lived in Southern US. No travel outside US. Animals: cat. One male partner

23

## **Question #5**

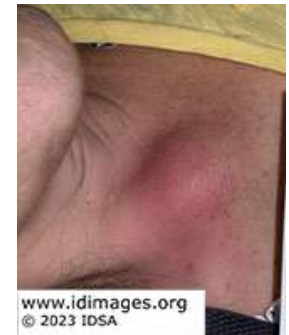### Physical exam

- Afebrile
- Nodule over wrist
- Swelling, right sternoclavicular joint



### Labs

- WBC 13.8
- CRP 266
- Serum ammonia 97 (elevated)
- Arthrocentesis: 194,000 nucleated cells (87% polys). Gram stain negative



24



### Question #5

#### What is the diagnosis?

- A. *Histoplasma capsulatum*
- B. *Ureaplasma urealyticum*
- C. Gonococcal infection
- D. Chronic Recurrent Multifocal Osteomyelitis (CRMO)
- E. *Borrelia burgdorferi*

25

### Diagnostic Procedure and Result:

- Synovial fluid aspirate of wrist: *Ureaplasma urealyticum* by 16S PCR analysis.

26

### *Ureaplasma urealyticum*

- Mycoplasmataceae family, along with *Mycoplasma* species
- Usually associated with genitourinary infections
- May cause infectious arthritis in people with immunocompromising conditions, such as hypogammaglobulinemia
- Disseminated *Ureaplasma* may mimic rheumatoid arthritis, including nodules
- Hyperammonemia due to IgA protease production by *Ureaplasma*.

27

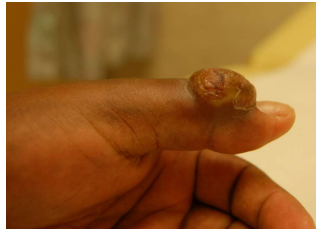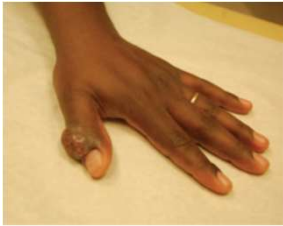### Question #6

- 35-year-old man of Ethiopian descent cut his left thumb with a knife while slaughtering a lamb as part of Easter festivities. He washed the wound with water and applied lemon juice and alcohol. One week later, he developed swelling and tenderness and a fluctuant lesion at the site.
- Two weeks after the injury, he underwent incision and drainage; cultures grew *Staph. aureus* (oxacillin sensitive). Treated with cephalexin but did not improve.

28

### Question #6

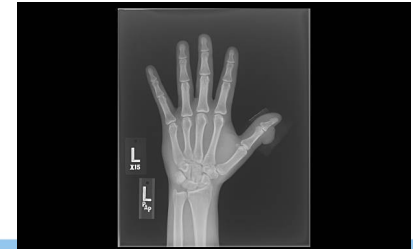Afebrile; 2 x 2 x 2 cm firm lesion on his thumb, without discoloration, purulent discharge, fluctuance, or bleeding



29

### Question #6

- Creatinine and LFTs normal. Glucose 158. WBC 4.2 (normal differential)
- X-ray: fungating soft tissue lesion on dorsal aspect of distal thumb; no underlying bone or joint abnormality

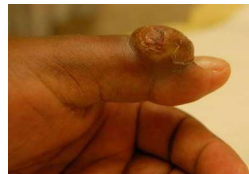
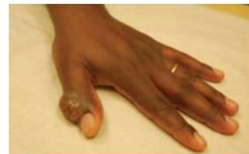
30

### Question #6

**What is the diagnosis?**

- A. Botryomycosis due to *S. aureus*
- B. Nocardia
- C. Brucella
- D. Orf
- E. Salmonella

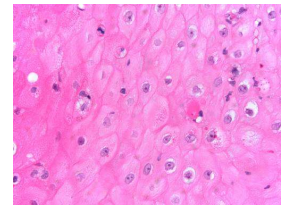


Contributors: Drs. Isaac Bogoch, Rajesh Gandhi

31

### Follow-up

- Lesion removed surgically
- Pathology: hyperkeratosis, epidermal necrosis, dermal infiltrate of mixed inflammatory cells; surface keratinocytes with eosinophilic inclusions
- PCR testing at CDC + for orf virus DNA



Appearance consistent with ecytha contagiousum

32



## Orf (Contagious Ecthyma)

- Zoonotic infection caused by a dermatropic parapox virus (ds DNA) of goats and sheep
- Transmitted by contact with infected animal or fomites
  - Animal handlers; children after visiting petting zoos, livestock fairs
  - Clusters reported after Eid, other festivities involving lamb sacrifice (Passover, Easter)

33

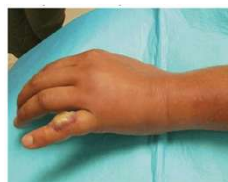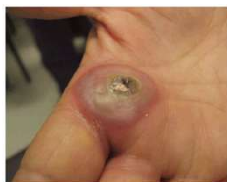## Orf (Cont.)

- 3-7 d incubation period
- Macule or papule → nodule with red center, white halo and peripheral erythema → ulcerative lesion → regenerative papilloma
- Most resolve in 4-8 wk
- Human-to-human transmission has not been reported
- Protective immunity incomplete; persons can be infected multiple times

34

## MMWR (April 13, 2012) highlighted 4 cases of orf associated with household meat processing or animal slaughter

- Bulla caused by orf virus infection after puncture by a bone of a recently slaughtered goat—PA, 2009
- Nodule caused by orf virus infection after contact with a lamb being sacrificed for a holiday — MA, 2010



35

## Question #7

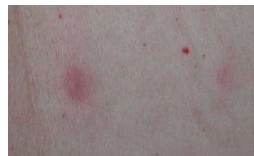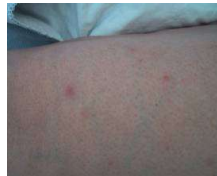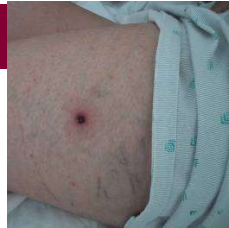- 50-year-old F was well until 7 days prior to admission when she noted “bite” on left thigh. Lesion enlarged over several days. Four days prior to admission, developed fatigue, arthralgias, myalgias, fever, headache. On admission (July), developed generalized rash on extremities, trunk, back.
- **SH:** Lived in New England. She had seen mouse in her basement. She had a dog. Denied sexual activity.
- **PE:** appeared well. T 100.5. No adenopathy. Lesion present on left thigh. Papular erythematous rash on her extremities, back, chest.

36

### Question #7

What does this patient most likely have?

- A. Varicella
- B. Monkeypox
- C. Cutaneous anthrax
- D. Rickettsialpox
- E. Lyme



### Rickettsialpox

- Caused by *Rickettsia akari*, member of spotted fever group of rickettsiae
- Transmitted to humans by mouse mite
- NYC outbreak in 1980s; high seroprevalence (16%) in IDUs in Baltimore
- After bite of infected mite, *R. akari* proliferates resulting in papule, ulcerates to form eschar
- 3-7 days later, high fever, chills and headache.
- 2-3 days after onset of fever, generalized papulovesicular rash (not involving palms, soles)
- Diagnosis: serologic testing. Treatment: doxycycline

37

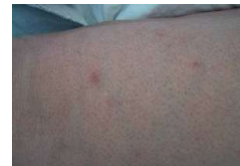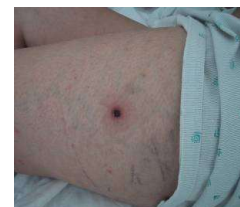38

### Rickettsialpox vs. Chickenpox

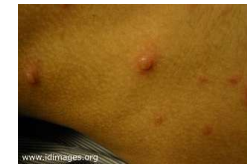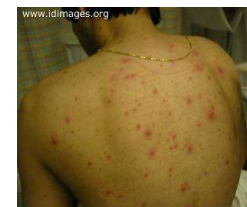	Rickettsialpox	Chickenpox
Eschar	Yes	No
Lesions in crops	No	Yes
Number of lesions	Relatively sparse (20-40)	Many
Mature lesion	Papulovesicle	Vesicle

Case contributed by Karen Thomas, M.D. and Leena Gandhi, M.D.

### Rickettsialpox



### Chickenpox



39

40

### Question #8

- Man in his 40s was well until 5 days before presentation when, in mid-spring, he developed headache. Two days later, he developed non-productive cough, throat discomfort and his eyes became watery and red.
- On 5<sup>th</sup> day of illness, while traveling to New England from Midwest, he developed a rash on face, upper arms & chest.
- Lived in Midwest with wife, teenagers, dog. Monogamous. Denied illicit drug use. Travels throughout US for work.

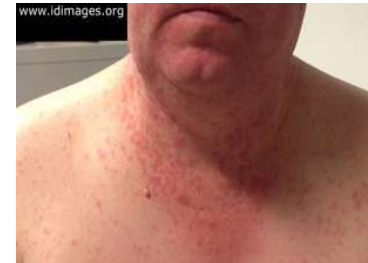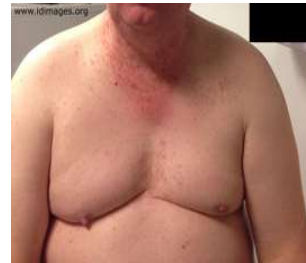Contributed by Drs. Jessica Haberer, Justin Chan, Rochelle Walensky

41

### Question #8

T 101. Diffuse erythematous, blanching maculopapular rash on face, trunk and arms. Conjunctival injection. Exam otherwise normal.

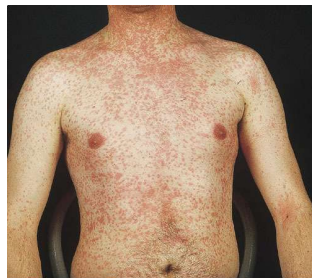WBC 3.3. Platelets normal.



42

### Question #8

**Rash in a different patient with same infection**



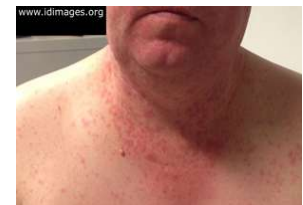Copyright ©2006 by The McGraw-Hill Companies, Inc. All rights reserved.

43

### Question #8

#### Differential Diagnosis

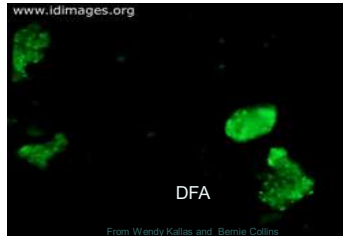
- A. Syphilis
- B. Scarlet fever
- C. Parvovirus infection
- D. Measles
- E. Rocky mountain spotted fever



44

## Measles

- Placed on airborne precautions
- Testing for influenza negative
- Nasal specimen positive for measles virus by direct fluorescent antibody (DFA)
- Measles IgM and IgG antibodies positive



Person in airport he was in had been diagnosed with measles of same genotype (imported case)

## Measles

- Acute febrile rash illness
- Airborne virus, contagious from several days before to several days after appearance of rash.
- Incubation period: 10-14 d from exposure to rash
- Prodromal sx: fever, cough, coryza, conjunctivitis
- Koplik spots may appear toward end of prodromal symptoms, just before rash
- Rash typically begins on face; then spreads down body to involve trunk and then extremities. Lasts 5-6 days.

45

46

## Question #9

Previously healthy man in his seventies presented with 2 weeks of fever, headaches, myalgias and 5 days of nonproductive cough, dyspnea, and fevers

### Epidemiologic history

- Lives in Southern California in mountain wilderness
- Leaves his vehicle outside with the windows down; frequently cleans dashboard and upholstery
- No domestic pets; surrounded by rodents, deer, sheep, raccoons, other wildlife
- Prior to symptoms, he had visited local zoo; no direct animal contact
- No other travel history outside the country; no known sick contacts

47

## Question #9

### Physical Examination

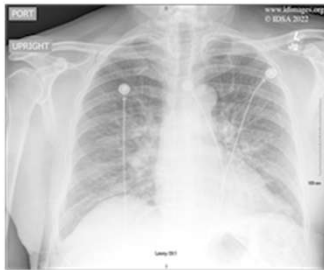
- Mild respiratory distress
- BP 141/80. Pulse 94. Temp. 97.7 °F, RR 20, oxygen sat 93% on 6 L oxygen by nasal canula
- Respiratory exam: rhonchi at the lung bases
- Examination was otherwise normal

### Studies

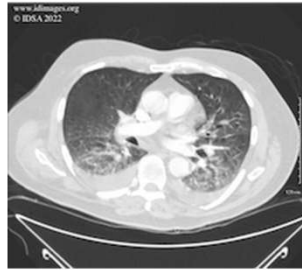- WBC 19.3; 10% atypical lymphocytes; no eosinophilia
- Hemoglobin 18.4 g/dL. Hematocrit 52.6%. Platelets 102,000
- Chlamydia pneumoniae, Mycoplasma, HIV-1/2, Coxiella serologies were negative
- *Legionella pneumophila* urine antigen were negative
- Respiratory viral panel negative

48

### Question #9 (Studies)



Chest X-ray demonstrating ground-glass opacities in the upper and lower lobes consistent with pneumonia.



Chest CT: Hazy ground glass densities in the lower lobes bilaterally with bilateral pleural effusions.

49

### Question #9

#### Clinical Course Prior to Diagnosis

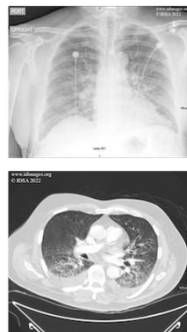
- Patient was admitted with diagnosis of community-acquired pneumonia.
- He was started on azithromycin and ceftriaxone.
- He was initially requiring minimal supplemental oxygen, however, his respiratory status worsened requiring high flow nasal canula at 20 L with fractional inspired oxygen of 80% saturation (FiO2%) during initial course of hospitalization.

50

### Question #9

#### What is the diagnosis?

- A. Coccidioidomycosis
- B. Legionella pneumonia
- C. Hantavirus Cardiopulmonary Syndrome
- D. Leptospirosis Pulmonary Hemorrhage Syndrome
- E. Tularemia



51

### Follow-up

- Hantavirus IgG and IgM serologies were positive.
- Patient improved and his symptoms resolved.

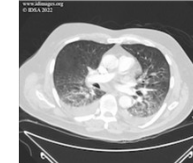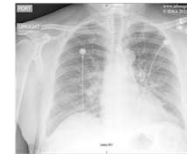52

## Hantavirus Cardiopulmonary Syndrome (HCPS): Clues

- Most cases are in southwestern US; first recognized in Four Corners region
- Transmitted by rodent reservoir, often in rural settings
- Febrile illness, bilateral interstitial infiltrates, and respiratory compromise requiring oxygen within 72 hours of hospitalization
- Cardiopulmonary phase characterized by capillary leak, hemoconcentration (elevated hemoglobin/hematocrit), shock, pulmonary edema
- Diagnostic test: serologic assays

## Final Diagnosis

- Hantavirus Cardiopulmonary Syndrome (HCPS)



Contributed by Dr. Dave Patel

 **INFECTIOUS DISEASE IMAGES**  
eMicrobes Digital Library

A Joint Project of the Massachusetts General Hospital Infectious Diseases Division and Microbiology Lab